TREATMENT OF STRIAE DISTENSAE USING CONTROLLED SUPERFICIAL EPIDERMAL INTERVENTION: THE BARBARA AGUIAR METHOD

Barbara Aguiar[1]

Abstract: Striae distensae (SD), commonly known as stretch marks, can be categorized as red striae with broken capillaries (Striae Rubrae) or late fibrotic white striae (Striae Albae). Treating stretch marks remains challenging due to the variable efficacy of treatments and the risk of post-inflammatory hyperpigmentation, particularly with treatments that act on the dermal layer. The Barbara Aguiar method involves a controlled epidermal intervention combined with the topical application of a hyaluronic acid-based serum and a nutrient-rich diet. This method has been shown to consistently reduce the appearance of stretch marks, improving their colour and depth.

Keywords: Striae Distensae; Epidermis; Hyperpigmentation

INTRODUCTION

Striae de distension (DE) are common skin alterations, of multifactorial etiology, with an important participation of hormonal alterations, and are frequently observed in periods such as puberty and pregnancy, as well as in situations related to cortisol alterations and the use of corticosteroids. DE predominantly affects women. From a pathological point of view, they are characterized by alterations and rupture of collagen, elastic and reticular fibers of the dermis associated with epidermal alterations.

Treatment remains a challenge due to variable efficacy and the risk of post-inflammatory hyperpigmentation, which varies with treatment, especially when it is reached The dermis (Chaudhury

1 Graduada em fisioterapia, Pós graduação em Estética e Cosmetologia , Formada em Medicina Tradicional Chinesa sistêmica e estética

et al., 2026).

Stretch marks can be classified into red stretch marks (Striae Rubrae) and white or mature stretch marks (Striae Albae) (Wu and Wang, 2026). Red stretch marks are characterized by the rupture of collagen, elastic, and reticular fibers, associated with the rupture of blood capillaries, responsible for the characteristic reddish color of the lesion. Contrary to what is often described, red stretch marks should not be considered easier to treat, since in addition to structural changes, they present a color change that also needs to be treated. Therefore, treatment should consider both the recovery of the structural aspect of the stretch mark and the improvement of the color change of the lesion (Chaudhury et al., 2026).

The treatment of stretch marks is usually organized by modality and by stage of injury: in the case of red stretch marks, the focus is usually on erythema and vascularization, while in stretch marks alba, the focus is usually on collagen remodeling and the repigmentation. The main treatments for stretch marks include topical products, lasers/light devices, radiofrequency, microneedling, peels, microdermabrasion, carboxytherapy, and combination regimens (Chaudhury et al., 2026; El□Domyati et al., 2016; Ibrahim et al., 2015; Karimipour et al., 2010; Seirafianpour et al., 2021; Wu and Wang, 2026).

In this article we demonstrate the step-by-step of a treatment for stretch marks that has been implemented for 13 years using microdermabrasion, a controlled epidermal intervention (Barbara Aguiar Method) and some results obtained.

Methodology - The Barbara Aguiar Method (MBA) for the treatment of stretch marks

Therapeutic protocol

Inclusion and exclusion criteria

The exclusion criteria are: patients with uncontrolled diabetes, using anticoagulants, with anemia, using corticosteroids, undergoing cancer treatment, and pregnant women.

Materials and patient preparation

Before the procedure, the patient is instructed not to apply cosmetic products or any other topical substances to the area to be treated. Before the beginning of the procedure, strict asepsis measures are adopted, including hand hygiene by the professional, the use of procedure gloves, sterile gauze and disposable sterile needle, the organization of the material in a clean field and the use of a disposable tissue exclusive to each patient. Next, skin asepsis is performed with 70% ethyl alcohol or chlorhexidine solution, according to biosafety protocols.

Standardized technique of the Barbara Aguiar Method

The procedure consists of the standardized induction of a controlled superficial epidermal abrasion, performed exclusively in the most superficial layers of the skin through precise and standardized movements, deliberately avoiding dermal penetration or diffuse capillary bleeding. The objective of the intervention is to promote a localized mechanical stimulus, capable of triggering the initial physiological cascade of tissue repair, preserving the structural integrity of the dermis.

The controlled removal of the most superficial layer of skin is performed by continuous movements, stretch mark by stretch mark, maintaining gentle, light and constant pressure; in this way, it does not cause cuts or bleeding. The movement should always be precise in the extension of the entire stretch mark, like a sweep; however, it should be done only once in each part of the stretch mark, to avoid cuts or deep injuries.

On our pain scale from 0 to 10, our patients usually report pain from 0 to 3. There has never been a vagal reaction.

The procedure is conducted until homogeneous hyperemia is obtained in the treated area, without bleeding. The absence of bleeding is used as an operational criterion to ensure that the

intervention remains restricted to the epidermis, avoiding direct damage to the papillary dermis. Therefore, homogeneous hyperemia is used as a clinical marker of the end point of the procedure, indicating a transient increase in microvascular perfusion due to the acute inflammatory response induced by superficial epidermal abrasion.

At the end of the procedure, a topical hyaluronic acid serum is applied, with the objective of maintaining the hydration of the skin barrier during the re-epithelialization process, minimizing transepidermal water loss, without direct biostimulatory purpose and favoring the physiological process of tissue repair. No other product is applied immediately after the session.

In the first days after the procedure, the formation of a thin superficial crust is observed, which corresponds to the expected evolution of the healing process. In approximately 10 to 15 days, the superficial changes become clinically imperceptible. Although clinical re-epithelialization occurs between 10 and 15 days, the process of remodeling of the extracellular matrix can remain active for several weeks, involving the progressive reorganization of collagen and elastic fibers, and may extend for approximately 60 days depending on the individual characteristics of each patient.

Post-procedure care

During the post-procedure period, patients are advised to avoid direct and indirect sun exposure to the treated area, as well as to perform aesthetic procedures and apply potentially irritating substances, including acids, chemical agents, and topical oils. During the first seven days, it is recommended to clean the treated area exclusively with antiseptic soap without triclosan. The home protocol consists of the application of a topical serum with hyaluronic acid, as directed by the responsible team. It also includes the daily intake of Verisol collagen capsules and hyaluronic acid (150 mg/dose). For stretch marks alba or mature, there is also a daily intake of beta-carotene (6,000 IU of vitamin A).

Expected chronology of tissue response

The interval between sessions is established according to the clinical presentation of the stretch marks and the evolution of the tissue repair process. For white stretch marks, a minimum interval of 30 days between sessions is recommended. For red stretch marks, an interval of approximately 60 days is recommended, respecting the time necessary for the resolution of the inflammatory response and for skin remodeling before a new intervention.

Red stretch marks, in addition to suffering the injury, are also hyperpigmented. After a week of dermabrasion, we started using a whitening active to help recover skin color. This active ingredient (for red stretch marks) contains hyaluronic acid, vitamin E, niacinamide, tranexamic acid, glycolic acid, palmitic and caprylic acid triglycerides, sunflower oil, grape seed oil, jojoba oil, rosehip oil and almond glycolic extract.

Each patient uses this product 2 to 3 times a day until the next session, in which it should not be applied. This product, dermatologically tested, will help lighten the skin in this region with dark stretch marks.

However, if the patient has dark and white stretch marks on the same lesion, she should not use this active ingredient to lighten, as this will prevent the synthesis of melanin in the area where there was loss of melanocytes.

Standardization, safety and reproducibility

The safety of the intervention is standardized through the adoption of biosafety measures, the use of sterile and disposable materials, the clinical follow-up of the participants, and the systematic recording of the clinical evolution throughout the follow-up period. Therefore, in order to ensure the reproducibility of the study, the materials used, the skin preparation procedures, the form of execution of the intervention, the post-procedure care, the products used, the intervals between sessions, and

the clinical evaluation criteria were previously defined and standardized, which allows the uniform application of the method to all study participants.

Biological rationale of the intervention

The proposed intervention consists of performing a superficial and controlled mechanical stimulation of the epidermis, associated with a nutritional supplementation protocol, with the objective of favoring the physiological mechanisms involved in tissue repair. The intervention triggers a controlled acute inflammatory response, characterized by the release of cytokines, growth factors, and other mediators that participate in the stages of healing, re-epithelialization, and remodeling of the extracellular matrix. Considering that stretch marks present structural changes characterized by the disorganization and reduction of collagen and elastin fibers in the dermis, it is assumed that the activation of these repair mechanisms, associated with adequate nutritional support for tissue regeneration processes, can favor the synthesis and reorganization of the extracellular matrix, contributing to the reduction of the depth of the stretch marks and to the improvement of the clinical appearance of the lesions. In addition, the epidermal renewal promoted by the intervention, in association with the nutrients involved in the maintenance of skin homeostasis, favors the gradual recovery of the uniformity of skin color, especially in hypochromic stretch marks, contributing to the overall improvement of the aesthetic appearance of the treated region. As there is tissue recovery, the treated lesions do not return.

RESULTS

All images were taken with the same camera, at the same distance, with the same lighting, and with the patient in the same position, without filters. All the cases presented here demonstrate a reduction in depth, recovery of coloration, and patient satisfaction with the treatment of stretch marks.

There were no adverse effects.

The elbow stretch marks were treated with the MBA (Figure 1). Total improvement was observed in the areas with stretch marks, which were completely closed. For the thicker and deeper stretch marks, there was no closure, but there was recovery of the skin and color. It is also possible to observe an improvement in the depth of the stretch marks (Figure 1).



Figure 1: Anterior elbow striations, with a thickness of 5 to 9 mm, in a male patient. Results after 1 session of the Barbara Aguiar Method (MBA).

The treatment of post-pregnancy dark skin on the side of the abdomen of the patient with 5 mm thick red and pearlescent stretch marks is shown in Figure 2. After 3 sessions of the procedure with an interval of 60 days, several stretch marks closed completely. Others involved skin restoration, and did not evolve to white stretch marks due to the treatment for full recovery of skin color (see methodology). White stretch marks with less deep lesions showed total improvement of lesions and color. In deeper stretch marks, there was partial improvement and, even so, closure occurred at 2

millimeters thick. It is also possible to observe an improvement in the depth of the stretch marks (Figure 2).



Figure 2: Dark post-pregnancy stretch marks on the side of the abdomen, red and pearlescent. The red ones are between 5 and 11 mm thick, and the white ones are 5 mm. Results after 3 sessions of the Barbara Aguiar Method with an interval of 60 days between one session and another.

Treatment was performed for a 50-year-old patient with old white stretch marks on the buttocks, developed during adolescence, with a thickness of 3 to 8 mm (Figure 3). Some stretch marks

were reduced to the point of disappearing, with a thickness of less than 3 mm. Stretch marks with a thickness of 8 mm recovered their color and reduced their thickness to 3 to 4 mm. It is also possible to observe an improvement in the depth of the stretch marks (Figure 3).



Figure 3: A 50-year-old patient with white and old adolescent stretch marks, with a thickness of 3 to 8 mm. 3 sessions of the Barbara Aguiar Method were performed, with an interval of 30 days between sessions.

Figure 4 shows stretch marks on the thighs with a thickness of 3 to 5 mm. The recovery after treatment was 100% in the stretch marks and coloration.

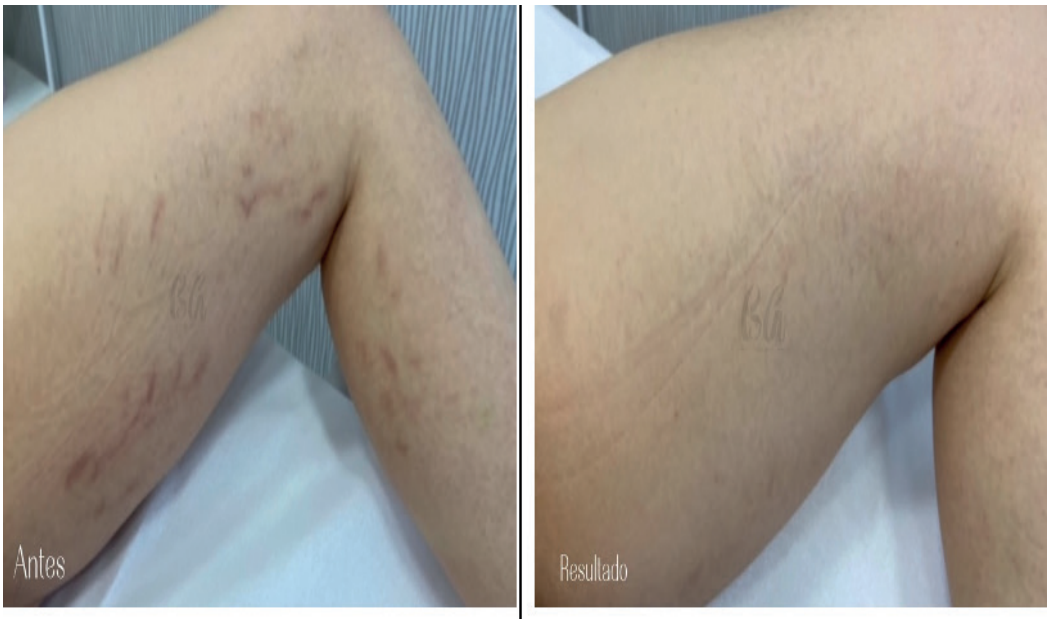

Figure 4: A 30-year-old patient with stretch marks on the thighs due to the use of corticosteroids. For red stretch marks, a total of 5 sessions were performed, with an interval of 60 days between them.

A 32-year-old patient with white postgestational stretch marks with a thickness of 2 to 5 mm, including 11 mm stretch marks in the navel region, is shown in Figure 5. After the sessions, we observed that the thinner stretch marks disappeared; the skin and color were fully recovered. The 5 mm stretch marks decreased to 2 and 3 mm, and the 11 mm stretch marks, in the umbilical region, showed improvement in color and flaccidity (Figure 5).

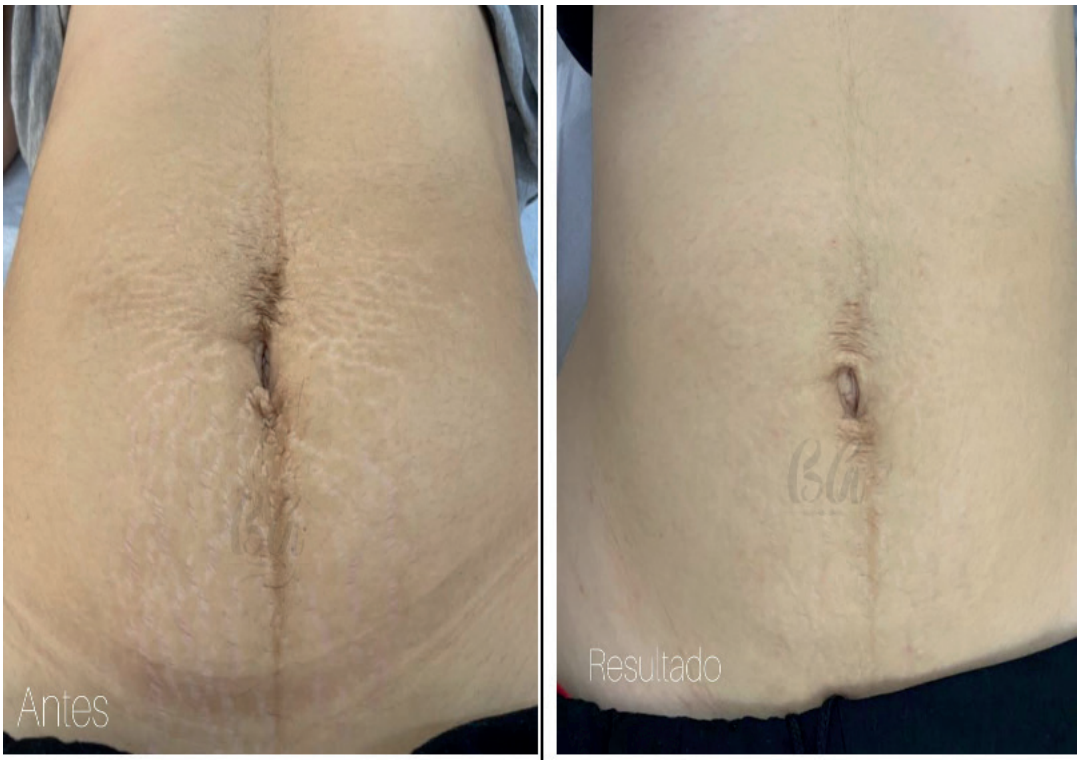

Figure 5: A 32-year-old patient with white post-gestational streaks. 3 sessions were performed, with an interval of 30 days between them.

Pain Scale (VAS), before, during and after treatment

Patients report pain from 0 to 3 on the pain scale, and the post-treatment maintains this pattern. Patients who do the whole body report burning in the post-treatment, with a pain scale of 4 to 6, especially at bath time and only on the first day. From the second day onwards, they no longer feel any discomfort.

DISCUSSION

Our microdermabrasion method (MBA), associated with the topical application of hyaluronic

acid-based serum for 7 days and the intake of nutrients for both red stretch marks and stretch marks alba, presents consistent results in reducing stretch marks and improving coloration.

In all reviews on the topic, there is no gold standard treatment, and most of the evidence is limited by small clinical trials, heterogeneous protocols, and measures with inconsistent results (Chaudhury et al., 2026). Stretch marks present epidermal atrophy, disruption of dermal collagen, and alterations in fibroblast signaling; therefore, communication between the epidermis and the dermis is a plausible mechanism to explain the results achieved here (Borrelli et al., 2022).

In this case, the dermal-epidermal junction appears to be structurally altered in stretch marks, with less deep dermal papillae and collagen flattening. Our method seems to corroborate that only a controlled abrasion of the epidermis can activate signaling pathways ("epidermal-dermal crosstalk") capable of inducing dermal remodeling, without direct mechanical injury of the dermis layer (Borrelli et al., 2022; El□Domyati et al., 2016). This hypothesis is biologically plausible and has already been discussed for microdermabrasion, but it still lacks robust clinical demonstration specific to stretch marks (Borrelli et al., 2022) . This pattern suggests that a superficial intervention produces a deeper, more restorative dermal response.

CONCLUSION

The Barbara Aguiar method consists of microdermabrasion, through superficial and controlled mechanical stimulation of the epidermis, associated with a nutritional supplementation protocol and topical creams. The treatment favors the physiological mechanisms involved in tissue repair of alba and red distension stretch marks.

REFERENCES

Borrelli, M.R., Griffin, M., Chen, K., Deleon Diaz, N.M., Adem, S., Mascharak, S., Shen, A.H.,

Ngaage, L.M., Lewis, N., Longaker, M.T., Gurtner, G., Wan, D.C., Lorenz, H.P., 2022. Profibrotic signaling pathways and surface markers are up-regulated in fibroblasts of human striae distensae and in a mouse model system. Plastic & Reconstructive Surgery 150, 327–338. https://doi.org/10.1097/PRS.0000000000009363

Chaudhury, H., Remmert, N., Chen, H., Tarbox, M., 2026. Advancements in treating stretch marks across all skin types: a comprehensive review of therapeutic modalities. International Journal of Women's Dermatology 12, e244. https://doi.org/10.1097/JW9.0000000000000244

El□Domyati, M., Hosam, W., Abdel□Azim, E., Abdel□Wahab, H., Mohamed, E., 2016. Microdermabrasion: a clinical, histometric, and histopathologic study. J of Cosmetic Dermatology 15, 503–513. https://doi.org/10.1111/jocd.12252

Ibrahim, Z.A.E., El□Tatawy, R.A., El□Samongy, M.A., Ali, D.A.M., 2015. Comparison between the efficacy and safety of platelet□rich plasma vs . microdermabrasion in the treatment of striae distensae: clinical and histopathological study. J of Cosmetic Dermatology 14, 336–346. https://doi.org/10.1111/jocd.12160

Karimipour, D.J., Karimipour, G., Orringer, J.S., 2010. Microdermabrasion: An Evidence-Based Review: Plastic and Reconstructive Surgery 125, 372–377. https://doi.org/10.1097/PRS.0b013e3181c2a583

Seirafianpour, F., Sodagar, S., Mozafarpoor, S., Baradaran, H.R., Panahi, P., Hassanlouei, B., Goodarzi, A., 2021. Systematic review of single and combined treatments for different types of striae: a comparison of striae treatments. Acad Dermatol Venereol 35, 2185–2198. https://doi.org/10.1111/jdv.17374

Wu, Y., Wang, H., 2026. Advances in the Treatment of Striae Distensae. J of Cosmetic Dermatology 25, e70683. https://doi.org/10.1111/jocd.70683